


PRESENTING CLINICAL SIGNS

History: Grade 4/6 murmur. Possible seizures/collapsing episodes. BP WNL. Recurring GI signs for past 3 months.

DATE

2/24/23

ECHOCARDIOGRAPHIC FINDINGS

2D, M-mode, and Doppler study.

PERFORMED BY:

Shari Reffi, CVT

INTERPRETED BY

 Keith Blass, DVM,
 MS, DACVIM
 (Cardiology)

There is moderate left atrial dilation. The mitral valve leaflets are thickened and exhibit systolic prolapse. A moderate jet of eccentric mitral regurgitation is present. There is mild to moderate left ventricular dilation. Left ventricular systolic function is mildly hyperdynamic. The aorta and aortic valve appear normal, though trace aortic insufficiency is present. Right atrial and right ventricular dimensions are normal. The tricuspid valve leaflets are mildly thickened, and a mild to moderate jet of tricuspid regurgitation is present. TR velocity is consistent with the presence of moderate pulmonary hypertension (PG 62 mmHg). The pulmonic valve appears normal. No pericardial effusion or cardiac masses are seen.

PATIENT

Ari Dixon

 LA - 32.1 mm
 LVIDd - 30.6 mm
 LVIDs - 16.7 mm
 FS - 45.4%
 RA - 22.3 mm
 LVOT - 1.26 m/s
 RVOT - 0.80 m/s
 TR - 3.96 m/s

SPECIES

Canine

ASSESSMENT/RECOMMENDATIONS

 Degenerative mitral and tricuspid valve disease
 Pulmonary hypertension

BREED

Cairn Terrier

This examination demonstrates regurgitation of blood across Ari's mitral and tricuspid valves resulting from degenerative valve disease. Ari has moderate mitral regurgitation present, with moderate secondary dilation of his left atrium and mild to moderate dilation of his left ventricle, as well as moderate secondary pulmonary hypertension. Both Ari's mitral valve disease and pulmonary hypertension are advanced enough to be able to result in syncope, therefore, one or both diseases are likely contributing to his collapsing episodes. In addition to syncope, Ari's is at risk for the development of a cough, exercise intolerance, and labored breathing, therefore, careful monitoring for these signs is recommended. Ari's tricuspid valve disease is milder, however, dogs with moderate pulmonary hypertension can develop right-sided congestive heart failure, therefore, careful monitoring for the development of peritoneal and/or pleural effusion is recommended.

14 y

I recommend starting Ari on pimobendan (2.5 mg am, 1.25 mg pm) and sildenafil (10 mg BID), as the former should help to slow the progression of his valvular diseases, the latter should treat his pulmonary hypertension, and both should reduce his risk for syncope.

WEIGHT

13.2 lb

A recheck echocardiogram is recommended in 6 months. Thoracic radiographs are recommended if Ari experiences respiratory clinical signs.

HOSPITAL NAME

Basking Ridge AH

REFERRING VET

Dr. Blachek



DATE

2/24/23

PERFORMED BY:

Shari Reffi, CVT

INTERPRETED BY

Keith Blass, DVM,
MS, DACVIM
(Cardiology)

PATIENT

Ari Dixon

SPECIES

Canine

BREED

Cairn Terrier

SEX

FS

AGE

14 y

WEIGHT

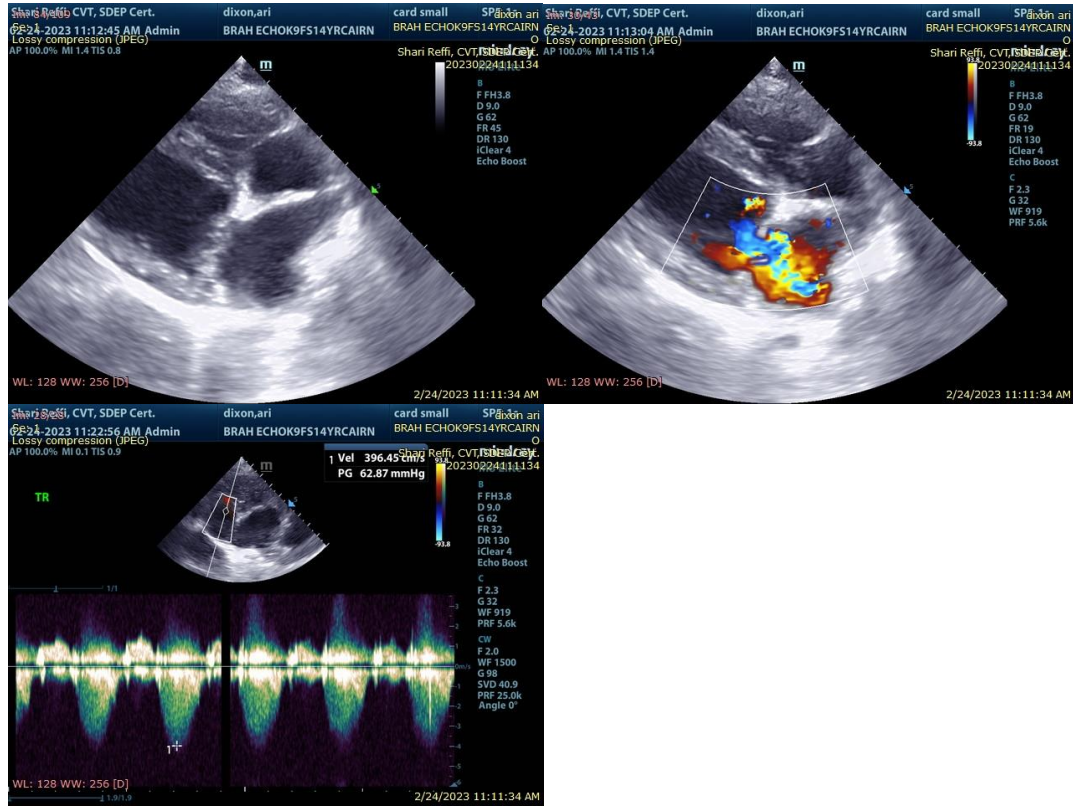
13.2 lb

HOSPITAL NAME

Basking Ridge AH

REFERRING VET

Dr. Blachek



The information and recommendations provided are based on the images presented by the referring veterinarian. No evaluation can be communicated regarding pathology that was not visible in the image/video clips provided.

Thank you for this referral. If the clinical or image interpretation does not parallel your findings or if I can be of any further assistance please contact me.

Keith Blass, DVM, MS, DACVIM (Cardiology)
KeithBlass@gmail.com
631-804-5754